In-NICU 1T MRI Is Clinically Equivalent to 1.5 or 3.0 Scanners for NICU Patients

A New Paradigm for Optimal Care of Neonates

Neonatal brain magnetic resonance imaging (MRI) carries significant safety risks to the infant both during transport outside of the controlled environment of the neonatal intensive care unit (NICU) and while performing the scan itself. To reduce these safety risks, hospitals are placing a dedicated MRI scanner within the NICU environment.

In 2020, a study using in-situ simulation of 10 neonatal MRI scans identified 116 latent safety threats related to the transport and scanning procedure. Safety threats fell in to three major categories: medication administration, equipment issues, and resource/system issues (#-Wong, 2020). Another significant and common risk related to neonatal MRI is temperature management. Bastug and colleagues found that 27% of neonates transported within the hospital for radiology services suffered episodes of hypothermia (1).

The Embrace® Neonatal MRI is the only FDA and CE approved dedicated neonatal MRI system. It also passes the American College of Radiology's MR phantom requirements for MRI accreditation. The in-NICU Embrace® Neonatal 1T MRI is a self-shielded permanent magnet and does not require a physically separate safety zone or radiofrequency shielded room (see sidebar for specifications). The system includes the Embrace® Patient Bed, which offers a temperature-controlled environment designed to support the needs of the neonate and minimize the possibility of hypothermia.

Embrace® Neonatal MRI System

Specifications

- Smaller footprint than conventional MRI with no special electrical requirements
- Less acoustic noise
- 1 T field strength, horizontal B0 field
- 5 Gauss line is within system cover
- 0 external magnetic field
- 150mT/m peak gradient strength

Imaging

- Sequences include gradient echo, spin echo, fast spin echo, MPRAGE, DWI and ADC maps, Irsnap (T1 mapping)
- Sharp, high resolution axial, sagittal, coronal, and oblique MR images
- DICOM images generated within minutes of scan for immediate viewing
- Stored on PACS systems

(SWI sequence as WIP package, not available at time of study described below, is also now available)

Placing the Embrace® MRI in the NICU also makes scanning more accessible for unstable neonates who cannot be safely transported outside the NICU, facilitates serial scanning of neonates with evolving brain injury, and is overall, less intrusive to the hospital's radiology schedule.

How Does the Embrace® MRI Compare to Conventional MRI?

The Embrace® Neonatal MRI System was developed to meet the unique clinical needs of the fragile neonatal population and to reduce the associated safety risks, however the essential question for any radiologists is: How do Embrace® MRI images compare to the typical 1.5T and 3T scanners?

To address this question, a comparative study was conducted in the NICU of Shaare Zedek Medical Center (SZMC) in Jerusalem, Israel.

The study compared the ability of experienced pediatric radiologists to identify normal structures, anatomical landmarks, and structural abnormalities in 55 premature infants using T1 and T2 weighted images from the Embrace MRI scanner and their 1.5T conventional MRI scanner (cMRI).
A secondary objective was validation ofADC maps producedfrom DWI images.

The inclusion criteria for infants in this study were:

a) Preterm birth before the 28th week of pregnancy or
b) Preterm birth between the 28th and 32nd weeks gestation and a clinical history of at least one of the following neonatal morbidities:
    i) Intraventricular hemorrhage (any grade); Cerebellar hemorrhage; Ventriculomegaly; Echodensities on cranial ultrasound after the age of 7 days; White matter abnormalities; Connatal cysts; Sepsis; Necrotizing enterocolitis; Surgery; Severe jaundice requiring an exchange transfusion;
    ii) and/or an abnormal neurological exam.

Scan Procedures and Radiologist Review of Images

Three independent reviewers (2 external pediatric radiologists, 1 SZMC staff radiologist) individually scored the visibility of specific predefined anatomical landmarks and cerebral pathologies on a scale of 1 to 4 (1=not visible, 2=partially visible, 3=good, 4=excellent). Composite scores for each patient were the average of the three reviewers' scores. Mean ADC values were read on prescribed regions of interest (ROI).

All 1.5T cMRI scans were performed within 72 hours of the 1T Embrace scans using a feed-and-swaddle technique; no sedation or anesthesia was given.

Visibility of Anatomical Landmarks for Embrace MRI vs. cMRI: Remarkably Comparable

The visibility of most anatomical landmarks was either identical or differed by a maximum of 1% between the devices. There was 100% agreement for visibility of the lateral, third, and fourth ventricular borders on images from both the 1T Embrace MRI and 1.5T cMRI. The caudate, putamen, and thalamus was visible in 99% of the images collected from both the 1T Embrace MRI and the 1.5T cMRI. Visualization of the cortex, white matter, choroid plexus, and globus pallidus differed by 1% using the 1T Embrace MRI vs. 1.5T cMRI (99% vs. 100%, respectively).

The posterior limb of the internal capsule (PLIC) was visible on 83% of the Embrace MRI scans and 90% of the cMRI scans. The lower visibility of the PLIC in both groups is likely due to developmental stage of the infants at the time of scanning. The study scans were conducted around the time of onset of myelination (typically GA 32-36 weeks). Additionally, the comparative scans were not completed on the same day. The 1.5T cMRI was performed up to 72 hours after the Embrace MRI. Therefore, the time between the comparative scans may have contributed to the difference in the overall visibility of the PLIC between the two devices; and may not be related to the difference in the scanners' field-strength (8).

Visibility of Abnormal Findings using the Embrace MRI vs. cMRI: Good Correlation

Ventriculomegaly and white matter abnormalities were among the most common abnormal findings identified in the study subjects. The correlation between the Embrace 1T MRI and 1.5T cMRI was good for all structural abnormalities observed, with no significant difference between the two devices (p≥0.05)

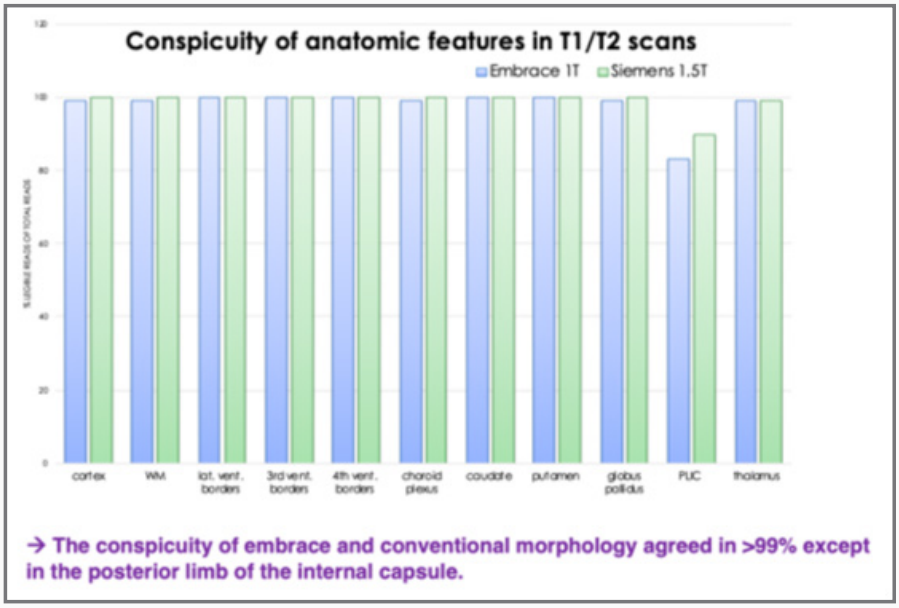

ADC for Embrace MRI and cMRI Were Similar

The Apparent Diffusion Coefficient (ADC) was measured in regions of interest (ROI) in the left and right frontal and occipital cortex, centrum semiovale of white matter, thalamus, and cerebellar lobes. Results were compared between the patient's left and right hemispheres, to reference values, and between the two devices. A normalized ADC ratio to account for ADC variation among scanners, magnetic field strengths, and matrix sizes was calculated as the mean ADC values in two white matter regions divided by the mean ADC value of the eyeball (7). The ADC calculation was found to be comparable between the Embrace MRI and the 1.5T cMRI.

Safety: Transit Time and Adverse Events

During the study, the time to transport each neonate to and from the in-NICU Embrace Neonatal MRI Scanner and the off-unit cMRI scanner was recorded. The round trip transit time from the patient's NICU bed to the Embrace in-NICU scanner was significantly decreased, as one would expect, when compared to the typical off-unit radiology transport. The total transit time to the conventional MRI was 48 minutes and the transit time to the Embrace in-NICU MRI was only 7 minutes ($p<0.0001$).

The use of the Embrace Neonatal MRI Scanner was also found to be safe for use in this study population; no adverse events were reported by the investigators while using the Embrace® 1T MRI scanner.

Image Comparisons – 1T Embrace Neonatal MRI and 1.5T and 3T Clinical Adult MRI Scanners

Image comparisons conducted at SZMC and the Brigham and Women's Hospital (BWH) in Boston, USA found similar results of clinical equivalence of images between the Embrace 1T MRI scanner and 1.5T and 3T clinical scanners.

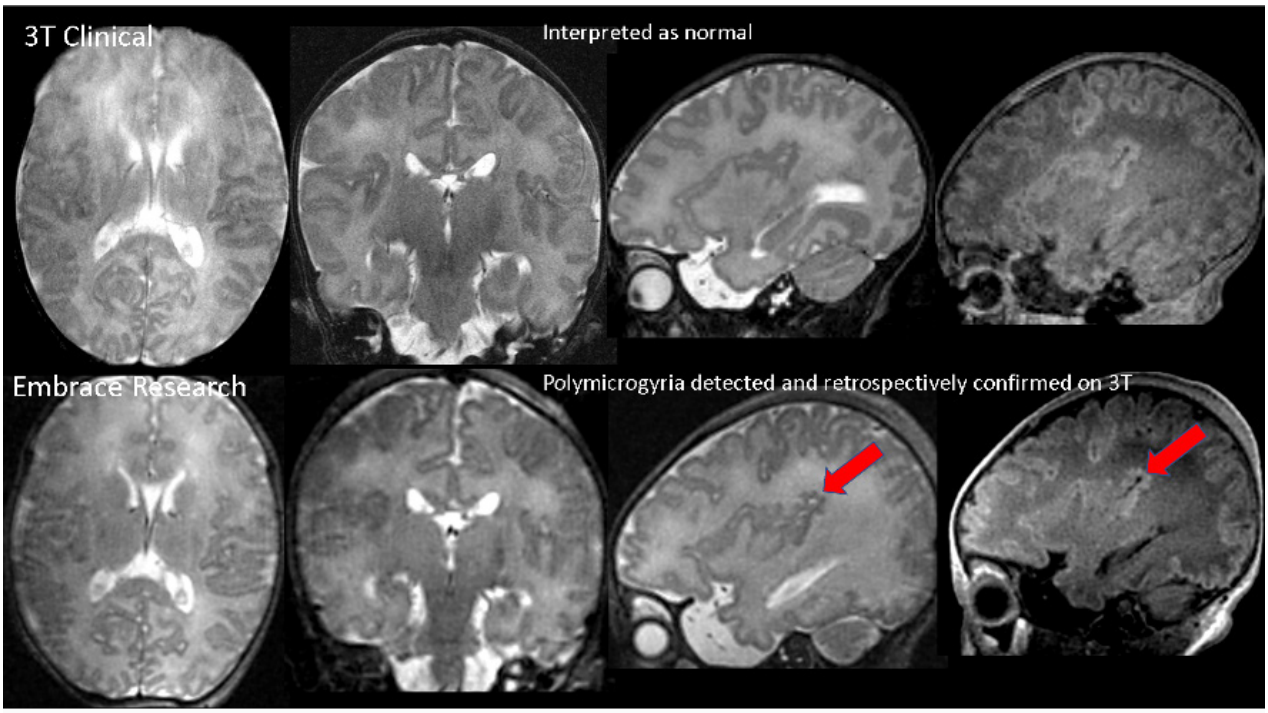

Figure 1: T1 and T2 weighted images from Embrace 1T In-NICU MRI & 3T Conventional MRI – History: Term infant with HIE, therapeutic hypothermia x 72 hours for severe encephalopathy. Incidental finding of polymicrogyria.

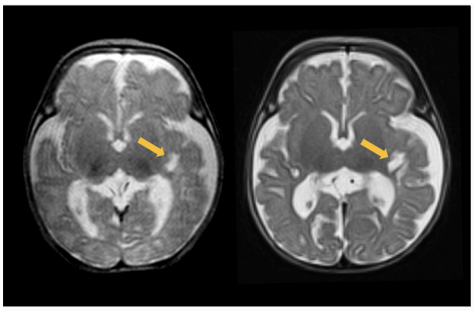

Figure 2: Cystic lesion

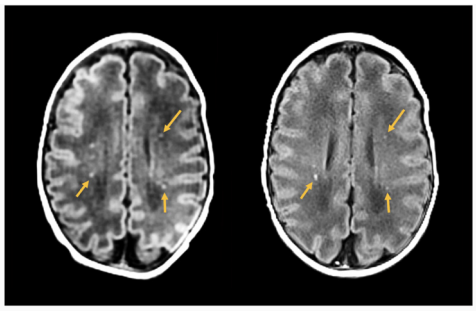

Figure 3: Focal WM

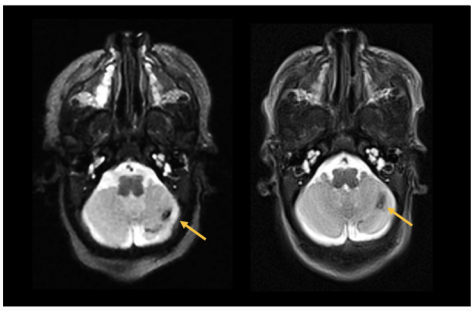

Figure 4: Focal Cerebellar

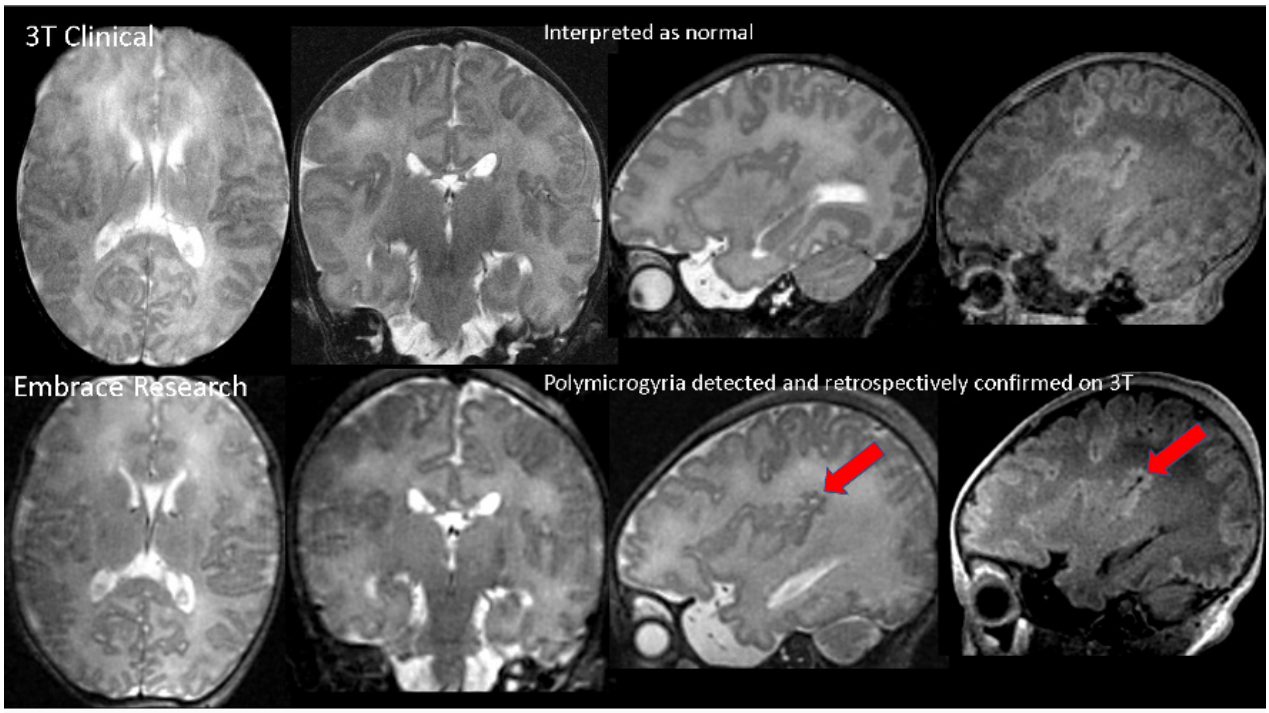

Figure 5: T2 Weighted, DWI, ADC. Term neonate with low Apgar scores, evaluated for HIE but did not qualify for therapeutic hypothermia. Readmitted to the NICU on day of life 3 with seizures. MRI showed focal area of restricted diffusion in left occipital lobe consistent with an arterial ischemic stroke. Coagulopathy disorder under investigation and early intervention and neurology follow up to be pursued after discharge. (Sept 2019)

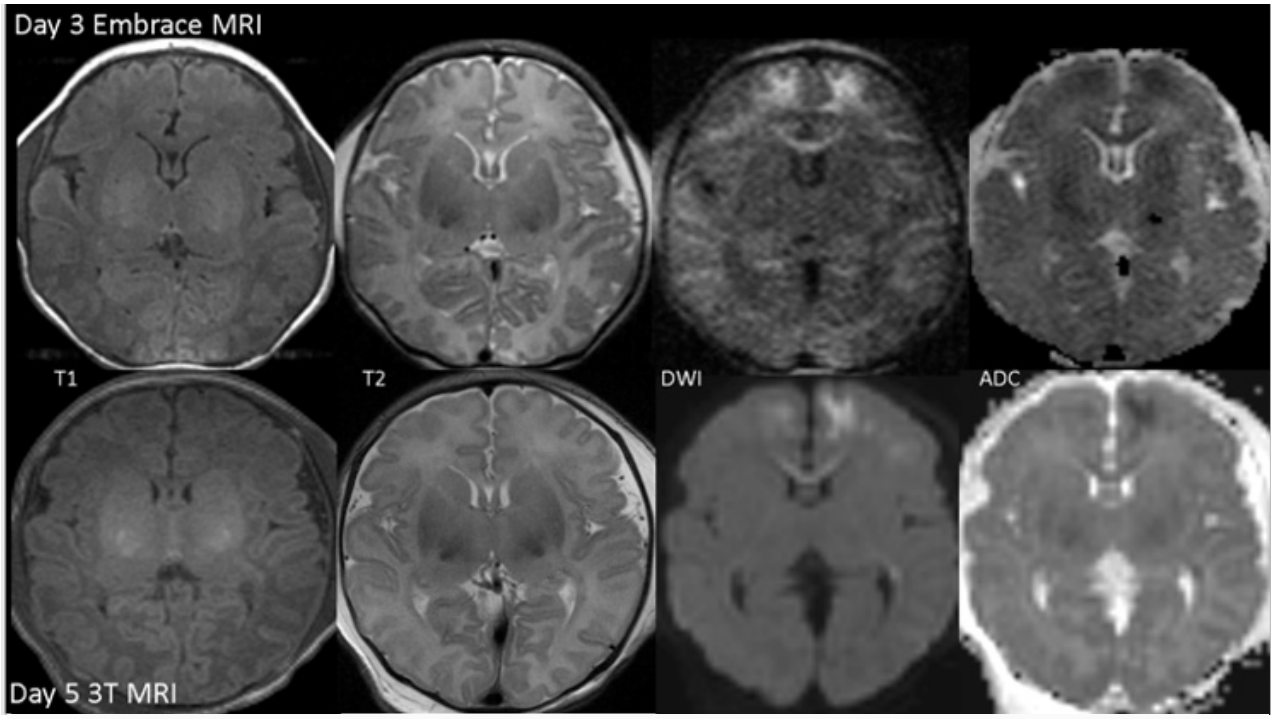

Figure 6: Term infant with severe encephalopathy, seizures, inotropes for hypotension, Day 3 in-NICU MRI scan using the Embrace 1T to determine direction of care. Focal frontal lobe white matter injury was reassuring for long-term outcome and intensive care was continued. Day 5 cMRI confirmed the extent of brain injury. (March 2019)

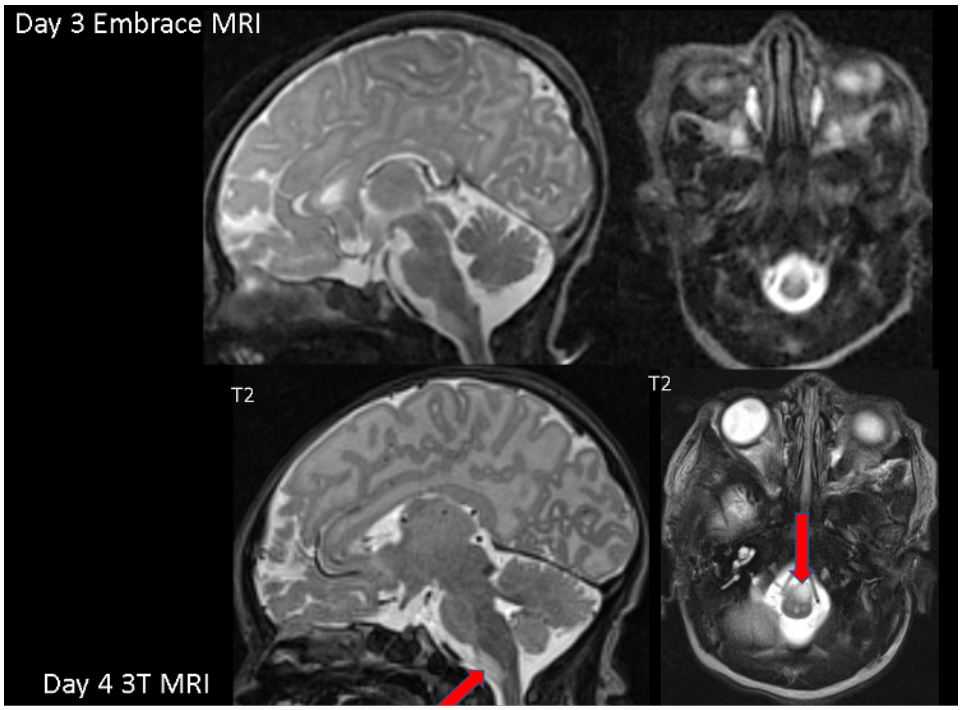

Figure 7: Term infant, evaluated for encephalopathy, not cooled, aEEG normal. Incidental finding of benign medullary tumor. (Nov 2020)

Summary

In conclusion, the Embrace Neonatal MRI in the NICU is a safe and clinically equivalent alternative to conventional MRI. Conventional MRI requires transport outside of the NICU for vulnerable neonatal patients posing preventable safety risks. The use of in unit, neonatal specific MRI may free up valuable time in Radiology's MRI unit schedule. Furthermore, the Embrace 1T MRI is the only FDA and CE approved dedicated neonatal MRI system, providing clinically equivalent image quality to the typical 1.5T and 3T adult MRI scanners with comparable ability to visualize anatomical landmarks and structural abnormalities.

References

1. Wong J, Kalaniti K, Castaldo M, Whyte H et al. "Utilizing Simulation to Identify Latent Safety Threats During Neonatal Magnetic Resonance Imaging Procedure." Simulation in Healthcare: The Journal of the Society for Simulation in Healthcare (2021): Journals@Ovid Full Text. Web. 14 February. 2021. <http://ovidsp.ovid.com/ovidweb.cgi?T=JS&PAGE=reference&D=ovftw&NEWS=N&AN=01266021-900000000-99461>.
2. Bastug O, Gunes T, Korkmaz L, et al. An evaluation of intra-hospital transport outcomes from tertiary neonatal intensive care unit. J Matern Fetal Neonatal Med. 2016;29(12):1993-8.
3. Stetson RC, Fang JL, Colby, CE, Jacobson RM. Improving infant vaccination status in a Level IV neonatal intensive care unit. Pediatrics. 2019;144(5):e20190337. doi: 10.1542/peds.2019-0337. Epub 8 Oct 2019.
4. Wu T-W, McLean C, Friedlich P, et al. Maintenance of whole-body therapeutic hypothermia during patient transport and magnetic resonance imaging. Pediatr Radiol. 2014;44(50:613-7.
5. Woodward LJ, Anderson PJ, Austin NC, et al. Neonatal MRI to predict neurodevelopmental outcomes in preterm infants. New Engl J Med. 2006;355:685-94.
6. Melbourne L, Chang T, Murnick J, et al. Clinical impact of term-equivalent magnetic resonance imaging in extremely low-birth-weight infants at a regional NICU. J Perinatol. 2016;36:985-89.
7. Rademaker K, Uiterwaal C, Beek F, et al. Neonatal cranial ultrasound versus MRI and neurodevelopmental outcome at school age in children born preterm. Arch Dis Child Fetal Neonatal Ed 2005;90(6):F489-F493.
8. Koontz NA, Wiggins RH. Differentiation of benign and malignant head and neck lesions with diffusion tensor imaging and DWI. Am J Roentgenol. 2017;208:1110-1115.
9. Battin M, Rutherford MA. 2002. Magnetic resonance imaging of the brain in preterm infants: 24 weeks' gestation to term. Part 2, Chapter 3 in MRI of the Neonatal Brain. Ed. Rutherford MA. Available at: http://www.mrineonatalbrain.com/ch02-03.php. Accessed: December 3, 2020.